

OBSERVATIONS ON NORMAL AND PATHOLOGICAL CYTOLOGY OF THE URINARY SEDIMENT

Gabriel Alin Iosob, Maria Prisecaru, Ionuț Stoica, Lidia Comănescu

Key words: renal pathology, urinal and sediment biochemistry analyzes

INTRODUCTION

Urinary sediment screening provides valuable information that corresponds to a significant number of clinical cases, a test of high importance in the diagnosis of many conditions that are determined by several factors. Regarding renal pathology, examination of urinary sediment provides data on the destructive-morphological and functional effect exerted on the kidney by various etiopathogenic factors, the frequent recurrence of the disease depending on its correct interpretation. Important influences on the sediment have the anatomic (morphological) factors, along with the biological, metabolic and physicochemical factors.

In order for the "pathological urinary sediment" syndrome to be properly analyzed, teamwork is needed between the laboratory specialist and the clinical specialist in order to obtain optimal therapeutic solutions. A negative value is given by the presence of epithelial and granular cylinders and the hyaline cylinders, erythrocytes and leukocytes have the same significance as proteinuria, hematuria and leucocyturia. Examination of crystals in the urinary sediment (crystals of uric acid, urate, phosphate, oxalate) is of special value. Description of urinary sediment is one of the most demanded laboratory tests, although the literature provides important information about urinary sediment. Scientific studies in our country are insufficiently addressed by this topic.

MATERIAL AND METHODS

As biological work material was used urine sediment from patients admitted to Bacău Emergency County Hospital who performed routine analyzes and patients with various symptoms and conditions. Urinary sediment analyzes were performed in the Bacău Emergency County Hospital Laboratory and in this paper data from January of this year (2017) were analyzed. This month, 3,263 urinal and sediment biochemistry analyzes were performed on the Sysmex UX 2000TM urine automatic particle

analyzer, of which only 321 samples required microscopic examination of the urinary sediment. Therefore, 90% of the analyzes performed did not require microscopic assessment and only 10% required this type of assessment (Figure 1).

RESULTS AND DISCUSSIONS

Of the 321 samples that required microscopic evaluation, samples with pathological values of the hematite, leukocyte, epithelial cells, cylinders, bacteria, crystals, yeasts, small round cells, pathological cylinders, and mucus from the urinary sediment were selected. Sum of 100 samples. The 100 pathological samples were recorded in tables and statistically and graphically interpreted with Office Excel 2016. Thus, it is clear from Figure 2 that the pathological evidence came from 36 males and 64 women. And 41% of patients come from urban and 59% from rural areas (Figure 3). In patients with urinary pathology, the most affected age group is 61-70 years, while the least affected age groups are 31-40 and 81-90 years (Figure 4).

In acidic or hypertonic urine, **erythrocytes** may contract to become pyriform or crenelate, simulating granulation, and in the alkaline or hypotonic (diluted) urine may swell by becoming round and licking. It is very important to mention the presence of deformed dysmorphic erythrocytes; A percentage > 30% indicates the origin of the glomerular hematuria.

The red blood cells can also occur in normal urine, fewer than 3-4 hematite in a field (on average). Above this number is discussed *microscopic hematuria*. When urine contains very abundant hematite (all covered microscopic field) is *macroscopic hematuria*. The presence of large amounts of red blood cells shows the existence of lesions that may have different origins.

In our study, it is clear from Figure 5 that some cases have very high values of red blood cells (cases 28, 64 and 94 - with malignant bladder cancer, case 48 with hypertension).

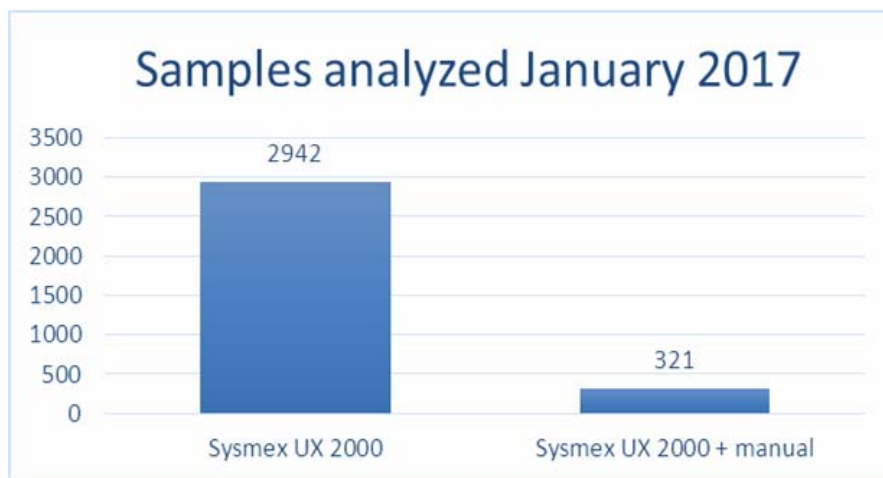


Figure 1. Number of urine samples analyzed and methods of analysis

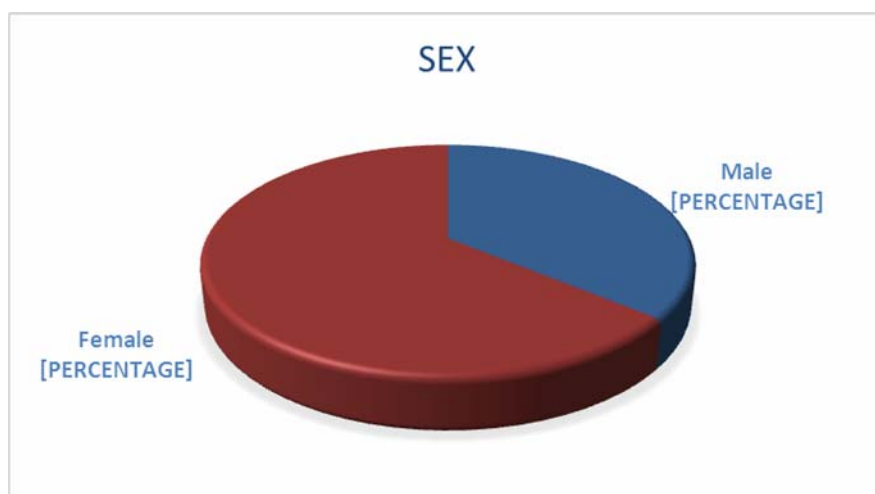


Figure 2. Percentage representation by gender

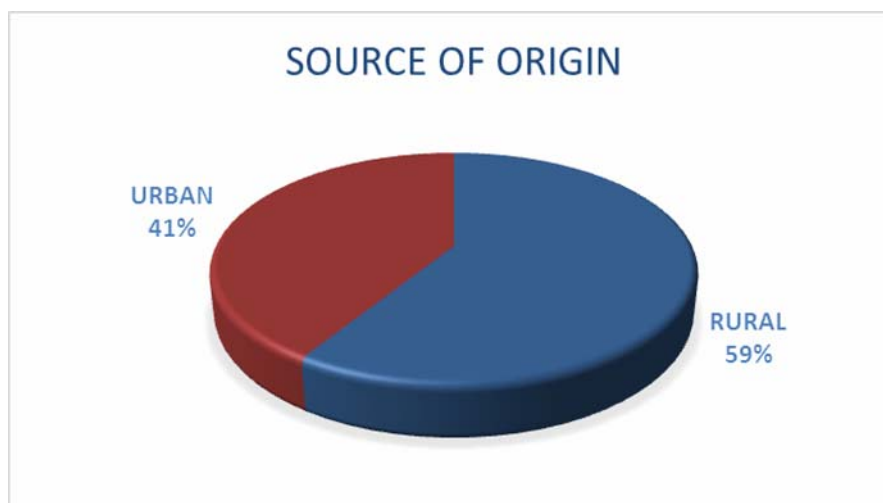


Figure 3. Graphic representation of the source environment

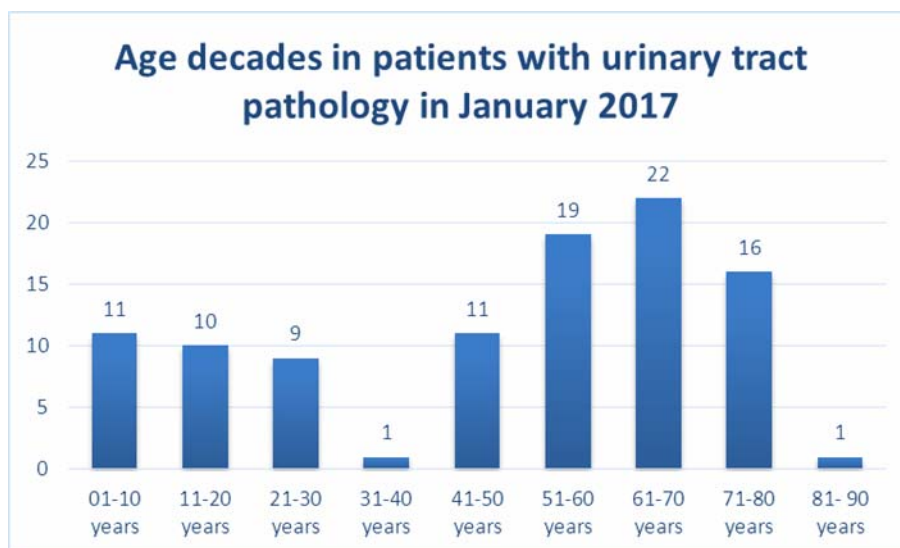


Figure 4. Percentage representation over decades of age of the investigated patients

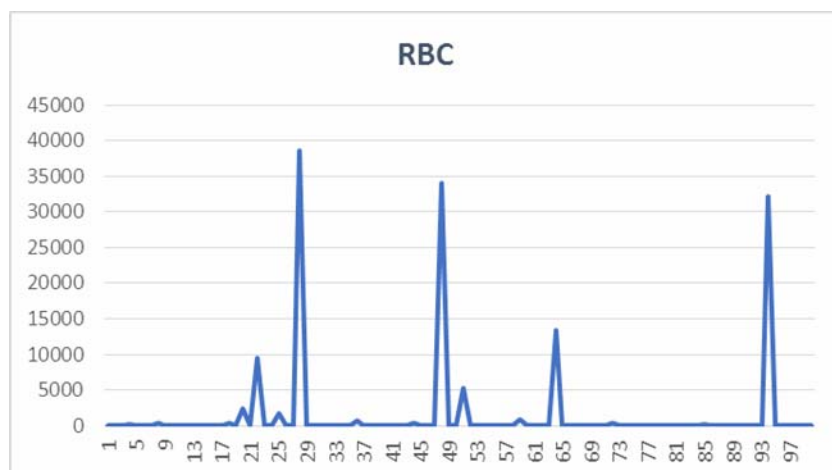


Figure 5. Graphical representation of the presence of red blood cells in urine sediment

Leukocytes normally appear in urine less than 10 in the field. They have the appearance of granular spherical globules, of different sizes, larger than erythrocytes; May appear isolated or clustered; Are mainly neutrophils and can be recognized by characteristic granulations and lobular nucleus. In normal urine there is a small number of leukocytes present. Leukocytes decrease in hypertonic urine; Swell and lysis in alkaline or hypotonic urine (in the alkaline or hypotonic urine leukocytes decrease by 50% within one hour at room temperature). Women may experience up to 40% false-positive results as a result of vaginal contamination.

From Figure 6 there are some cases of very high leukocyte counts (19 cases with febrile syndrome, 22 with mioasteric syndrome, 44 with acute cystitis, 48 with hypertension, 51 with inflammatory syndrome).

An increased number of leukocytes suggests an inflammatory process in the urinary tract or adjacent areas. When their number is very high and shows a degraded aspect (pyuria) or clustered, an acute urinary tract infection is suspected. Sometimes, pyuria also occurs in acute non-renal conditions such as appendicitis or pancreatitis. It may also occur under non-infectious conditions such as glomerulonephritis, renal tubular acidosis, dehydration states, stress and irritative lesions of the ureters, bladder or urethra.

Due to its importance, the presence of clustered leukocytes should be reported. An increased number of lymphocytes and plasmocyte suggests acute renal graft rejection, and the increased eosinophil count is associated with tubulo-interstitial nephritis.

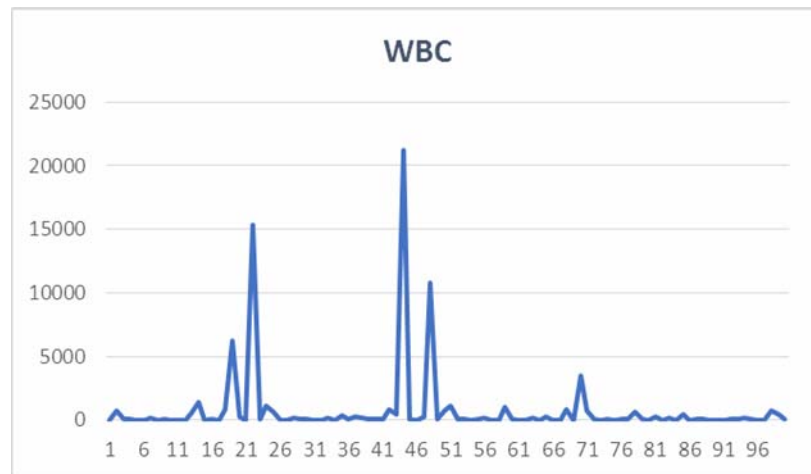


Figure 6. Graphical representation of the presence of leukocytes in urine sediment

Urine epithelial cells can originate in any portion of the urogenital tract, starting from the proximal tube to the urethra or vagina. They normally meet in the urine as a result of physiological desquamation of senile cells. A significant increase indicates inflammation in the urinary tract area from which these cells are derived. Three types of epithelial cells can be reported: renal, transient and squamous tubular cells.

In the present study it is clear from the Figure 7 that a large number of samples have high values of the number of epithelial cells present in the urinary sediment (cases 4 with liver cirrhosis, 13 with hyperemesis pregnancy [severe vomiting], 14, 24, 35 with labor false, 29 with lumbar discopathy, 65 with acute cystitis, 76 with lymphadenitis, 92 with heart failure, 93 with osteoporosis).

Urine cylinders are formed in the lumen of the renal tubules as a result of the precipitation of Tamm-Horsfall mucoproteins (secreted by the renal tubules) or cell agglutination/other materials in a protein matrix; Some cylinders (waxy cylinders) may contain serum proteins. The factors involved in the formation of the cylinders are urinary stasis, increased acidity, the presence of protein constituents and abnormal ionic load. Urinary cylinders usually associate with proteinuria, but can also be found in the absence of this. The origin of the cylinders is always renal, indicating intrinsic renal disease. Thus, they may be present in glomerular, tubular, kidney infections.

Cylinders are classified based on the appearance and the cellular components in their composition. Sometimes it can be difficult to differentiate because of degeneration or mixed composition. The breadth of the cylinders indicates the size of the renal tubules in which they are formed; Cylinder size is described as narrow (as 1-2 erythrocytes), medium (3-4 erythrocytes) and large (5 erythrocytes). Large cylinders are formed in collector tubes; Their presence usually indicates significant

reduction in functional ability of nephron and terminal renal disease.

The meaning of the cylinders is different depending on their type. Hyaline cylinders are the most common cylinders in the urine.

Figure 8 shows that many patients have uranium cylinders in the sediment, some have not been identified, some have rare cylinders (3-4 / field), others have relatively frequent crystals (5-10 / field), such as cases 16 (pleurisy), 41 (gastritis), 46 (acute pneumonia), 92 (heart failure), 95 (irritable bowel), 97 (acute laryngitis), 98 (gastric degeneration).

The presence of **bacteria** in the urine is a common phenomenon due to contamination with vaginal microbial flora or external urethral meatus, and because of the ability of bacteria to rapidly multiply in urine at room temperature.

The presence of bacteria in urine should be interpreted in the clinical context. Bacteria (microbial flora) present in the freshly correctly harvested urine and accompanied by a large number of leukocytes usually indicate a urinary tract infection. In the case of suspicion of urinary incontinence, it is necessary to perform a urocultivation.

The development of bacteria can cause a uniform opalescence of urine, which is not removed by heating, acidification, or filtering with filter paper. The smell of these urine specimens is usually unpleasant and generally ammoniacal, due to the breakdown of urea by bacteria. When this cloudy urine is examined at M.O., it is most often seen in the form of sticks, sometimes mobile, (*Echerichia coli*, *Proteus* sp.). However, ports are also encountered, such as *Enterococcus* sp.

In Figure 9 patients with a high number of bacteria / field are numerous: cases 2, 3, 7, 13, 14, 18, 19, 20, 21, 22, 24, 29, 33, 35, 38, 42, 48, 49, 55, 59, 62, 63, 65, 68, 69, 71, 72, 76, 78, 80, 81, 85, 93, 96, 98, 99.

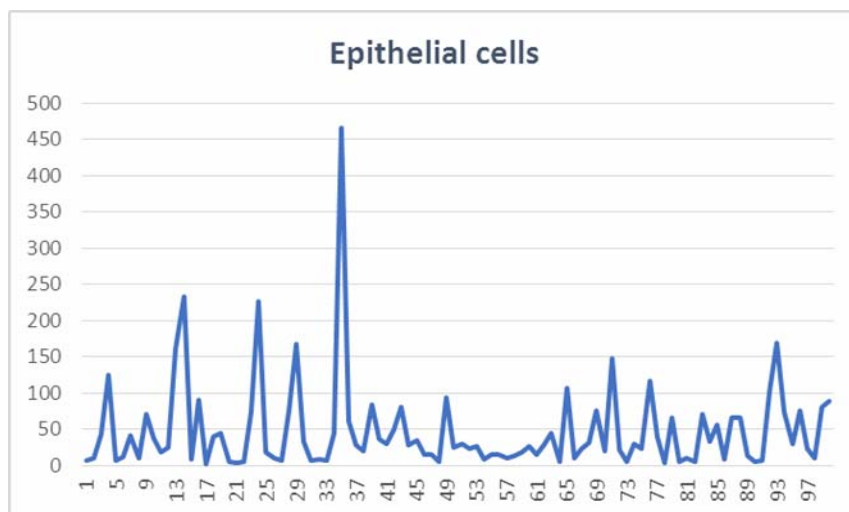


Figure 7. Graphic representation of the presence of epithelial cells in the urinary sediment

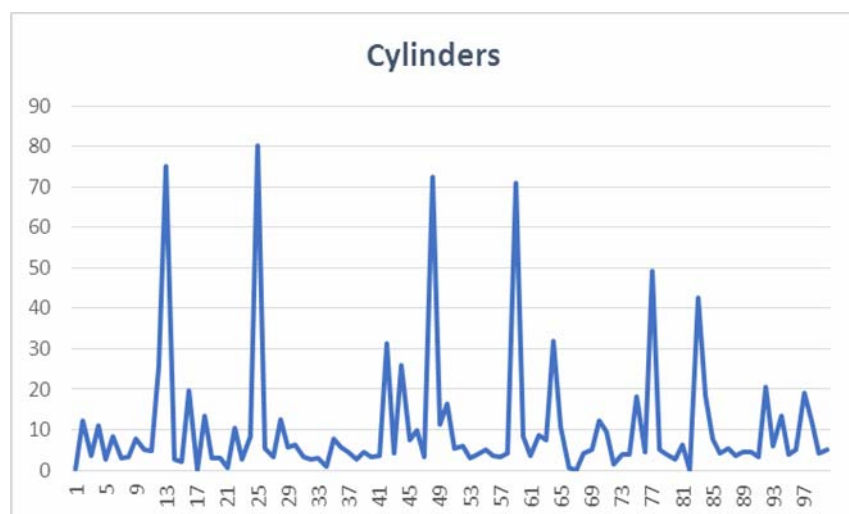


Figure 8. Graphic representation of the presence of cylinders in the urine sediment

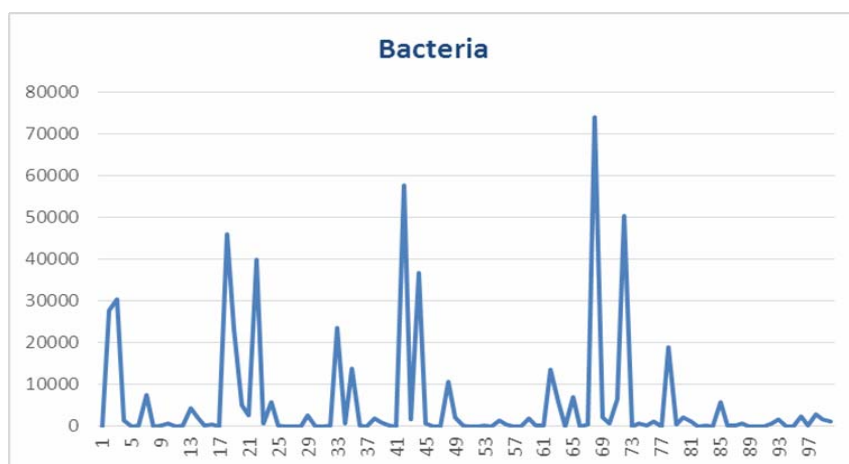


Figure 9. Reprezentarea grafică a prezenței bacteriilor în sedimentul urinar

Crystals are not usually found in the freshly emitted urine, but can occur after longer time at room temperature. Crystals are formed when the urine is over-saturated with a certain crystalline compound or when its solubility properties are altered.

If precipitation occurs in the kidney or urinary tract, the consequence is the formation of urinary calculi.

Most of the crystals that can be found in urine have low clinical importance, except in the case of metabolic imbalances, calculus formation, or medication regulation.

Crystals can be identified by appearance or, if necessary, by their solubility properties; Urinary pH strongly influences the formation of crystals.

The crystals commonly found in *acid urine* are: uric acid, calcium oxalate and amorphous ureas; Other types are present: calcium sulphate, sodium urate, hippuric acid, cystine, leucine, tyrosine, cholesterol, drug crystals.

Other types of crystals are found in *alkaline urine*: ammonia - magnesium phosphates (triphosphate), amorphous phosphates, calcium carbonate, calcium phosphates, ammonium biurets. Triple phosphate crystals can meet in normal urine, but can also form urinary calculi;

Can be found in chronic cystitis and skin, prostate hypertrophy, urine retention. Calcium phosphate crystals are also associated with urinary tract formation.

In the present study, Figure 10 shows that the presence of crystals in the sediment of investigated patients is quite frequent, from crystals absent, to rare crystals (3-4 / field), and even frequent (11-25 / field), as are cases 15, 17, 20, 29, 34, 45, 49, 67, 76, 93; Case 51 suffering from paraplex with biparse; Inflammatory syndrome, has the highest value of 2265 frequently hated amorphous.

Yeasts can occur in urinary tract infections, especially in diabetic patients; They may also be encountered as a result of skin or vaginal contamination. *Candida albicans* is the most common scab.

Cases where yeasts (*Candida albicans*) have been identified in the urinary sediment are: 18, 19, 24, 25, 43, 44, 51, 66, 67, 72, 77, 94 (Figure 11).

In addition to the microscopic examination, the Sysmex UX-2000TM analyzer can also display "research" parameters: crystals, small round cells (including both epithelial and renal tubular cells), leukemia-like cells, pathological cylinders, sperm; In these situations, however, the analyzer will give warning messages, and the samples will be re-examined by conventional microscopic technique.

In our study, **small round cells** were present in all sediment samples in Figure 12. In large numbers they were identified in cases 28, 83, 94. **Pathological cylinders** were present in larger numbers in cases 12, 25, 37, 40, 44, 48, 84 (Figure 13).

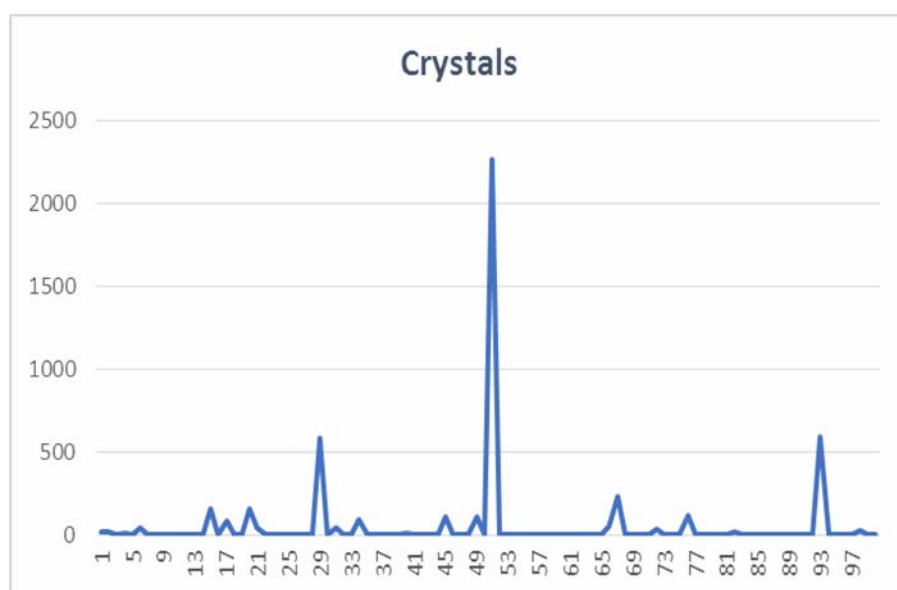


Figure 10. Crystal representation of the presence of crystals in urine sediment

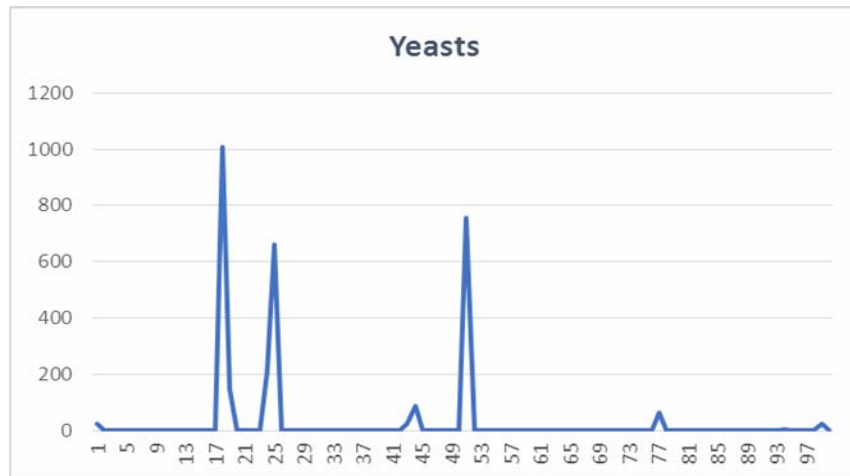


Figure 11. Graphic representation of the presence of yeasts in urine sediment

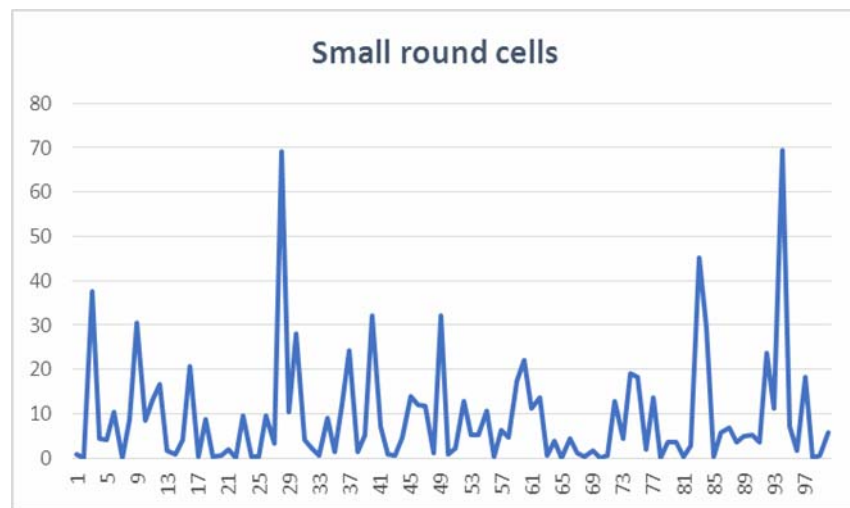


Figure 12. Graphic representation of the presence of small round cells in the urinary sediment

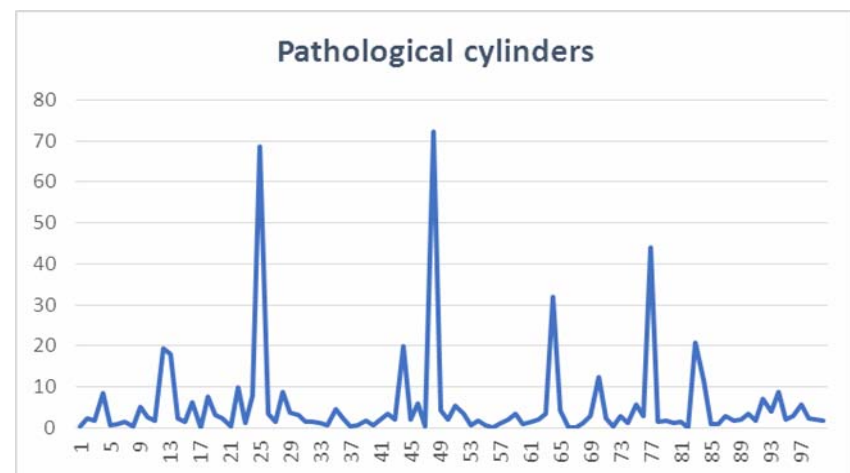


Figure 13. The graphical representation of the presence of the pathological cylinder in the urinary sediment

The amount of mucus may be of genital or urinary origin. Mucus fibers appear in small numbers in normal urine, but their number may increase in the case of inflammation or irritation of the urinary tract.

In women, mucus in a reduced amount can normally come from the genitals. However, the large amount of mucus in the urine may be signs of bladder inflammation - cystitis.

Mucus in urine *in men* is often a sign of inflammation of the urethra. Infection can penetrate the urinary tract and other lesions in the body, but most of the time, inflammation is caused by bacteria from the genitals. This is also the case with sexually transmitted diseases such as gonorrhea or chlamydia.

Figure 14 is the presence of mucus in urine sediment samples. 8, 10, 11, 12, 31, 36, 45, 46, 49, 58, 75, 84, 86, 87, 97.

Spermatozoa and prostatic fluid, mucus in the male genital tract can cause fluffy, bulky deposits. Spermatozooids occur in men's urine due to nocturnal emissions, epileptic seizures, genital diseases or sperm. They may occur in both sexes following sexual intercourse.

In our study, spermatozoa was not identified in any urine sediment sample, which also indicates a correct urine collection.

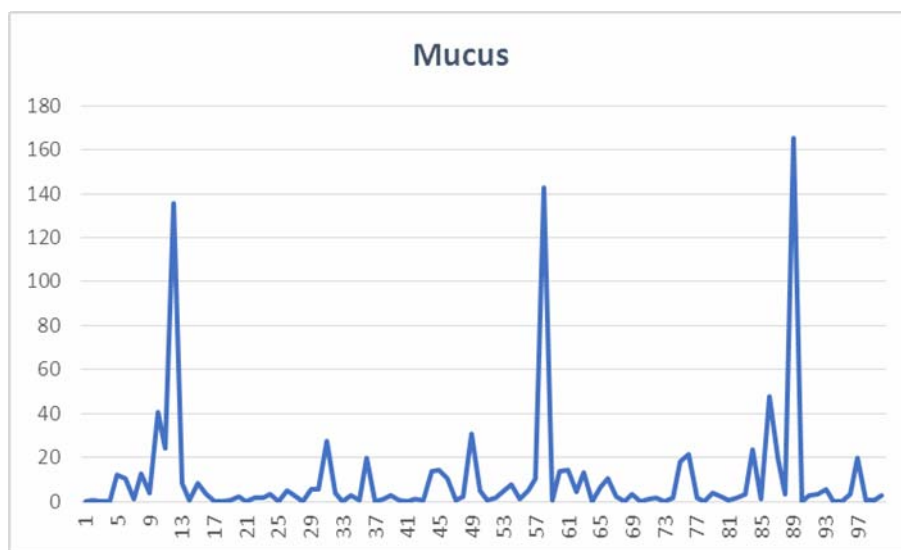


Figure 14. Graphical representation of the presence of mucus in the urinary sediment

CONCLUSIONS

Automated analyzers such as the Sysmex UX-2000TM improve efficiency by increasing productivity and reducing labor and the time needed to process urine analyzes. Along with the microscopic exam, the Sysmex UX-2000TM can also display other parameters of clinical importance.

All 100 investigated patients presented urinary sediment with modified elements that fall into urinary pathology.

ABSTRACT

In January of this year, 3.263 urinal and sediment biochemistry analyzes were performed in the Emergency County Hospital of Bacau, in the Sysmex UX 2000TM urine analyzer, of which only 321 samples required microscopic examination of the urinary sediment. Of the 321 samples that required microscopic evaluation, samples with pathological values of the hematite, leukocyte, epithelial cells, cylinders, bacteria, crystals, yeasts, small round cells, pathological cylinders and mucus from the urinary

sediment were selected summed up 100 samples. The 100 pathological samples were recorded in tables and statistically and graphically interpreted with the Office Excel 2016 program. All 100 investigated patients presented urinary sediment with modified elements that fall into the urinary tract

REFERENCES

1. BAUCHWITZ M.A., 1976 – Systematic cytology of the urinary tract , în CARDOZO P. L. (ed.) - Atlas of Clinical Cytology , Targa b.v. 's-Hertogenbosch; 419 – 434;
2. BAYER Healthcare Division (BAYER CORPORATION), 1996 – Modern Urine Chemistry Manual – Application of urine chemistry and microscopic examination in health and disease (ed. FREE M.H.) BAYER Inc. 77 Belfield Road Toronto, Ontario M9W 1G6;
3. BAYNES J.W., DOMINICZAK M., 2005 — Medical Bio-chemistry, Ed.2, Elsevier Mosby, p. 315-344;

4. BLACKBURN V., GRIGNANI S., FOGAZZI G.B., 1998 - Lipiduria as seen by transmission electron microscopy-*Nephrol Dial Transplant*;13: 2682-2684;
5. BONVENTRE, J., 2008— Kidney Injury Molecule-1 (KIM-1): A specific and sensitive biomarker of kidney injury, *Scand J Clin&Lab Invest*, 68 (S241): 78-83;
6. BUIUC, D.; NEGUȚ , M., 1999 - *Tratat de microbiologie clinică*, Editura Medicală, București. (Treated Clinical Microbiology, Medical Publishing House, Bucharest, 1999);
7. DUMITRASCU V., GLJU S., GRECU D.Ș. , 2007 — Sedimentul urinar, Ed de Vest Timișoara, 42-289. (Urinary sediment, The western Timisoara publishing house, 2007, 42-289);
8. FOGAZZI G.B., FENILI D, 1997 - Urinalysis and microscopy în DAVISON A.M.,CAMERON J.S.,GRUNFELD J-P., KERR N.S., RITZ E.,WINERS Cr.G.,(ed.) - *Oxford Text Book of Clinical Nephrology*, Oxford University Press;
9. HENRY J. B., 2001 — *Clinical Diagnosis and Management by Laboratory Methods*, 20th Ed, Saunders, p. 367-402;
10. IVANOVICI G., FUIOREA IOANA, 1990 - *Diagnosticul de laborator în practica medicală*, Bucuresti, Ed. Militară (Laboratory Diagnosis in Medical Practice, Bucharest, Military publishing house, 1990);
11. ZOSIN,C.,1979 - *Nefrologie clinică*-Editura Medicală, București. (Clinical Nephrology-Medical Publishing House, Bucharest, 1979).

AUTHORS` ADDRESS

PRISECARU MARIA, STOICA IONUȚ -
University „Vasile Alecsandri” Bacau, Faculty of
Biology, Marasesti Street, no. 157, Bacau, Romania,
e-mail:

prisecaru_maria@yahoo.com;
ionut_stoica23@yahoo.com.

IOSOB GABRIEL ALIN - Doctoral School -
University „Vasile Alecsandri” Bacau, Faculty of
Biology, Marasesti Street, no. 157, Bacau, Romania,
e-mail: iosob.gabriel@gmail.com;

COMĂNESCU LIDIA - Bacau Emergency
County Hospital, Romania, e-mail:
lidia_comanescu@yahoo.com